

---

**CASE REPORT****Acute Promyelocytic Leukemia in Four Year Old Female Child - A Case Report**

Anirudha V. Kushtagi<sup>1</sup>, Mihir J. Bhalodia<sup>1\*</sup>, Mahesh H. Karigoudar<sup>1</sup>, Jyotirling Savle<sup>1</sup>

<sup>1</sup>Department of Pathology, BLDE University, Shri B M Patil Medical College, Bijapur - 586103  
(Karnataka), India.

---

**Abstract:**

Leukemia is the most common malignancy of childhood representing about 30 % of oncohematological diseases diagnosed in children less than 15 years of age. We report the case of a 4 year old girl with acute promyelocytic leukemia whose blasts showed the morphology characteristic of acute promyelocytic leukemia variant. The case is reported because in the paediatric population the acute promyelocytic leukemia is a rare occurrence moreover, it represent a true oncohematology emergency, in this case the laboratory has a significant role since the timing of diagnosis must be very short. It helps in therapeutic protocols compared to conventional therapeutic protocols in Acute Myeloid Leukemia (AML), the introduction of retinoid All-Trans-Retinoic Acid (ATRA), both in children and adults with Acute Promyelocytic Leukemia (APL), has significantly reduced the early mortality.

**Keywords:** Acute Promyelocytic Leukemia (APL), All-Trans-Retinoic Acid (ATRA), Leukemia, Oncohematology, Retinoid, .

**Introduction:**

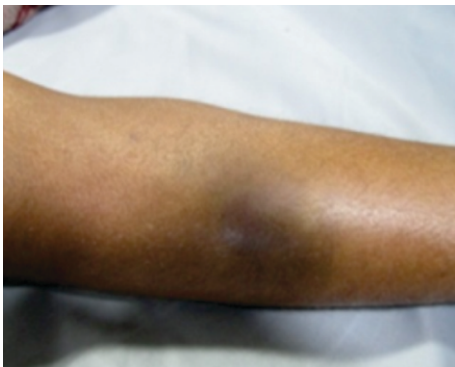Leukemia is the most common malignancy of childhood representing about 30 % of oncohematological diseases diagnosed in children less than 15 years of age. In childhood most cases of leukemia are acute leukemia and are characterized essentially by the lymphoid B-population involvement [1]. Acute myeloid leukemia (AML) in paediatric field represents the 15-20 % and the related mortality is approximately 30 %.

AML incidence in children is about 5-7 cases per million children year, the incidence peak is 11 cases per million in children under two years of age [1]. AML incidence is very low at around 9 years of age during adolescence it is 9 cases per million approximately. Between paediatric AML the incidence of acute promyelocytic leukemia (APL) is <10% [1]. In a multicenter Italian study, the APL was diagnosed in approximately 30 % of paediatric AML. As part of the AML, APL represents a distinct subtype that affects the treatment significantly.

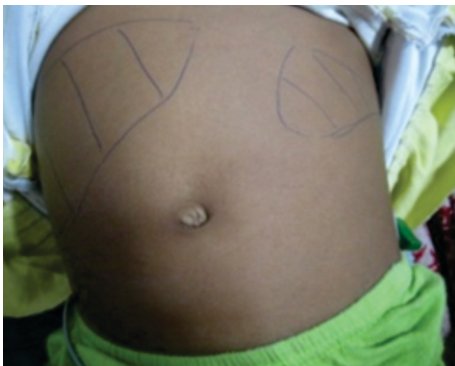Differentiation therapy of APL has subsequently undergone further refinements and results from 2007 show that up-front use of ATRA/ATO plus induction chemotherapy leads to complete remission rates in excess of 93 % with these patients achieving 5-year overall survival rates approaching 100 %. The majority of AML cases are characterized by specific single chromosomal alterations encoding leukemogenic proteins that function as constitutive transcriptional repressors of differentiation and programmed cell death and in common with APL [1].

**Case Report:**

We report the case of a four-year old girl who arrived at the emergency room of hospital for the presence of extensive bruising and petechiae located in the lower limbs (Fig. 1) and significant bleeding gums.



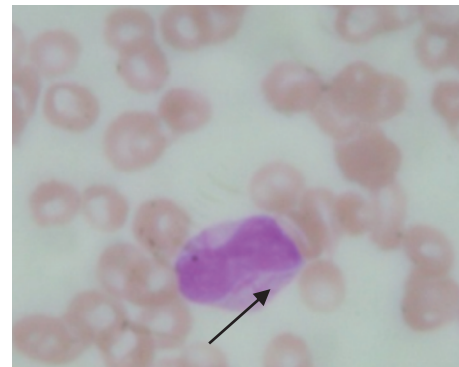**Fig. 1: Petechiae Over Limbs**



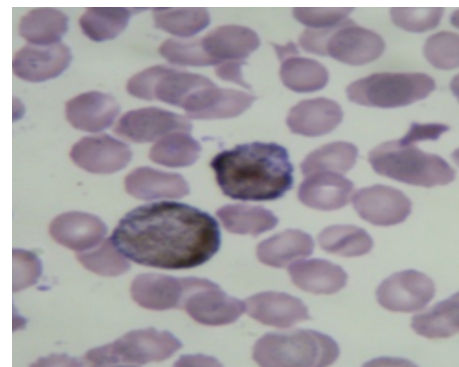
**Fig. 2: Hepatosplenomegaly**

The heart rate was 133/min, O<sub>2</sub> saturation 98% with massive hepatosplenomegaly (Fig. 2) and lymphadenopathy. The complete blood count showed severe normochromic anemia (Hb = 5.4g/dl, Ht = 21%; MCHC = 27g/dl) and severe thrombocytopenia (PLT = 0.30 lakhs/ $\mu$ l). There was leukocytosis (WBC =  $127.9 \times 10^9/L$ ) and the automatic differential leukocyte count showed neutrophilia (Neutrophils = 70%)

In this case given the analytical data, the morphological evaluation of peripheral blood smear is mandatory. The leukocytes differential count obtained with light microscopy showed neutropenia (Neutrophils =  $0.81 \times 10^9/L$ ), moreover the blood smear showed several blasts with small and stubby cytoplasmic Auer roads, nucleus often atypical appearance or Internuclear bridge (Fig. 3 & 4).



**Fig. 3: Blast with Bilobed Nucleus and Auer Road (Arrow)**



**Fig. 4: Blasts Myeloperoxidase (MPO) Positive**

The presence of myeloperoxidase positive blast population oriented towards an AML, and the distinctive morphology of the blasts give evidence for APL-M3. Because a specialized paediatric oncohematology department is not present in our hospital, after a few hours the patient was referred to another hospital and post referral follow up was not possible.

#### **Discussion:**

In children the APL is rare. Morphologically the classic APL is characterized by the presence of blasts promyelocytes hyper granulate > 20% with intracytoplasmic auer rods that in several cases, for their high number, form the so-called "faggot cells". In the APL-M3 the blasts show abnormal intracytoplasmic granules, the nuclei are bilobed or have a monocytoid appearance [1].

Three other morphological subcategories of APL were reported: APL with basophilic morphology, APL with M2-like blasts morphology, and APL with M1-like blasts morphology (early promyelocytic). The new WHO classification includes the APL between "AML with recurrent cytogenetic abnormalities"; other cytogenetic abnormalities and specific genes involved in AML are AML1/ETO, inv 16, and MLL. The APL variants genetically are uncommon and in most cases show the transcript PML/RAR $\alpha$  isoform bcr 1 and bcr 2 [2].

The immunophenotype frequently expresses the positivity for CD13 and CD33 antigens but does not express HLA-DR, CD34, and CD11b. In some studies the CD56 positivity at diagnosis is associated with poor outcome [1]. In our patient the presence myeloblasts, auer rods in peripheral smear study and myeloperoxidase positive blast population oriented towards an AML, and the distinctive morphology of the blasts give evidence for APL-M3. We have not performed immunophenotyping and cytogenetic study.

Clinically, in children as with adults, the APL is characterized by a high incidence of leukocytosis (WBC  $>10 \times 10^9/L$ ), as well as the APL-M3v and it is an important prognostic factor. In our patient count was  $127.9 \times 10^9/L$ . Patients with WBC  $>5 \times 10^9/L$  or  $>10 \times 10^9/L$  generally have a poor outcome. Furthermore, patients with leukocytosis at diagnosis can present positivity for FMS-like tyrosine kinase 3 (FLT3) internal tandem duplication (ITD) (FLT3/ITD); the leukocytosis with FLT3/ITD positivity represents a bad prognostic factor [3]. Morphologically over 25 % of paediatric APL appear as microgranular APL variant. About 75% of patients at diagnosis have significant DIC (Disseminated Intravascular Coagulation) with major bleeding events that impact on outcome. Compared with other AML, hepatosplenomegaly

and lymphadenopathy in APL are uncommon.[1] Our patient presented with hepatosplenomegaly but lymphadenopathy was not observed. With regard the gender, some paediatric therapeutic trials reported a slight increase of APL in females [1] as seen in our case.

The APL is associated with a specific chromosomal abnormality, the t(15;17) translocation [2]. The translocation affects the break point that involves the Retinoic Acid Receptor, producing a "Promyelocytic Leukemia (PML)" protein fusion with "Retinoic Acid Receptor- $\alpha$  (RAR- $\alpha$ )", the rearrangement forms the gene fusion PML/RAR- $\alpha$ , specific marker of disease. It was not until 1980 that various compounds, among them the retinoid all-trans-retinoic acid (ATRA), were found to induce differentiation in an AML cell line and APL (but not other AML subtype) patient samples [2].

Around the same time, a research group based in Shanghai and New York had started to screen for differentiation inducers (including ATRA) and this led to the first ATRA-based treatments in 1985 for APL patients harbouring the t(15;17)(q22;q21) translocation that encodes the promyelocytic leukaemia (PML)/retinoic acid receptor  $\alpha$  (RAR $\alpha$ ) fusion oncoprotein [3]. Although ATRA, in unprecedented fashion in oncology, was able to induce complete remission as a single agent, all cases eventually relapsed. In contrast, rarely occurring t(11;17)-associated APL, which expresses the promyelocytic leukaemia zinc finger (PLZF)/RAR- $\alpha$  fusion oncoprotein, is resistant to ATRA- induced differentiation therapy due to unabated transcriptional repression[1].

Subsequent incorporation of induction chemotherapy into the treatment strategy significantly improved long-term patient survival. In 1992, it was reported that Ailing-1, a traditional Chinese medicine containing high levels of arsenic trioxide

(ATO), induced dramatic remissions in APL patients, even those that had relapsed and were resistant to ATRA treatment [4].

Compared to conventional therapeutic protocols in AML, the introduction of ATRA, both in children and adults with APL, has significantly reduced the early mortality due to bleeding. This therapeutic approach should not lead to misunderstanding of the "Retinoic Acid Syndrome", also known as retinoic acid differentiation syndrome [4].

In about 80% of the paediatric cases the introduction of ATRA has led to the cure of APL [1]. The problem of relapse remains open. Understanding the molecular pathogenesis of APL and the subsequent introduction of new therapeutic

regimens is required for the cure of the disease. It is also important to understand the epidemiology of the disease in paediatric field according to geography.

#### Conclusion:

Paediatric APL is uncommon. It represents a true emergency in oncohematology. Haematological laboratory plays an important role in early diagnosis of APL, its management and outcome.

#### Acknowledgments:

Authors would like to thank Dr. L H Bidri, Pediatrician, Ashwini Hospital, Bijapur for his cooperation. Also authors would like to thank Dr. Raju Mali and Dr. Swami for their support.

#### References:

1. D'Angelo G, Ceriani L, Hotz AM, Mazzola D, Ranalli R. Acute promyelocytic leukemia in four year-old female child. A case report. *Adv Lab Med Int* 2012; 2(3): 110–118.
2. Stiller CA. Epidemiology and genetics of childhood cancer. *Oncogene* 2004; 23: 6429–44.
3. Passmore S J *et al.* Paediatric myelodysplastic syndromes and juvenile myelomonocytic leukaemia in the UK: a population-based study of incidence and survival. *British Journal of Haematology* 2003; 121: 758–767.
4. Hasle *et al.* Monosomy 7 and deletion 7q in children and adolescents with acute myeloid leukemia: an international retrospective study. *Blood journal* 2007; 109: 4641-4645.

\**Author for Correspondence:* Dr. Mihir J. Bhalodia, Post Graduate Student, Dept. of Pathology, Shri B M Patil Medical College, Bijapur - 586103 (Karnataka), India.  
Cell: 09591363189, E-mail: dr.mihirbhalodia@yahoo.com